

blue[®]m

Following the TOOTh guidelines for an angular bone defect

Drs. R.A. Muts

Following the TOOTH guidelines for an angular bone defect

case report

Anamnesis

Male, 59 years old

Angular bone defect distal of 36

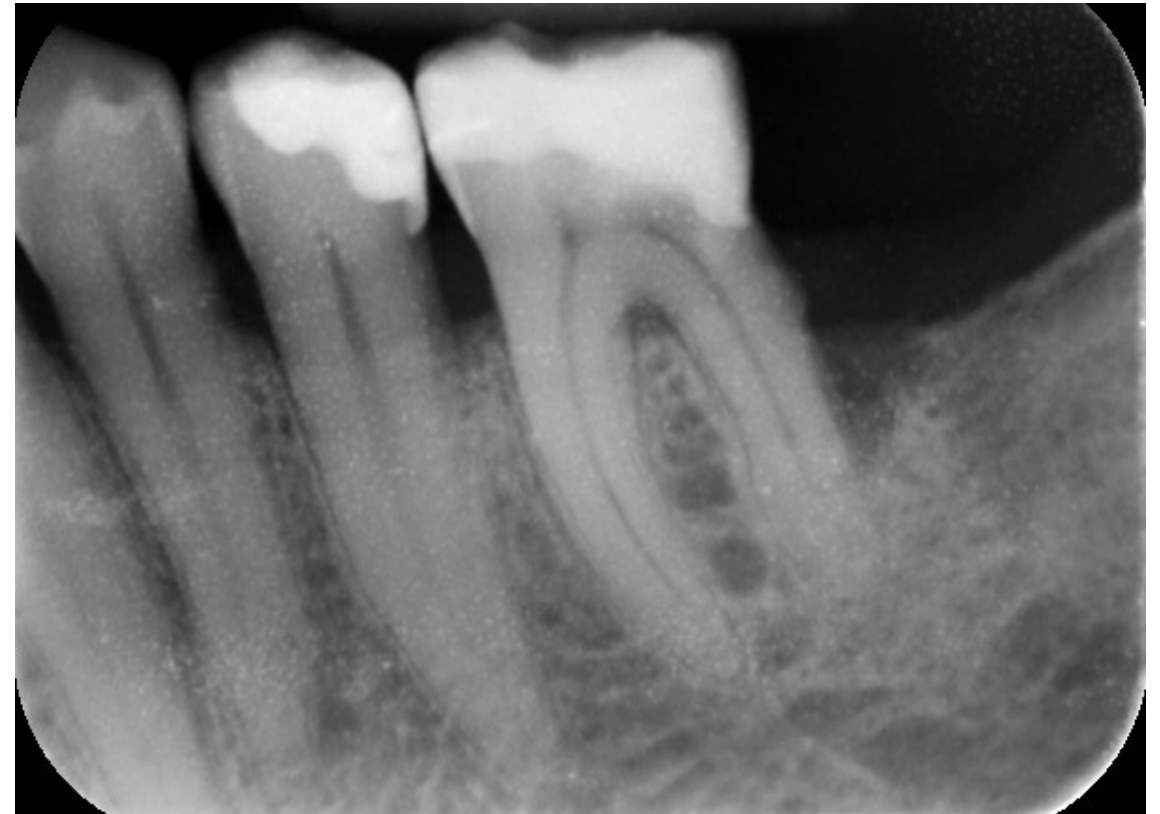
Pocket of 8 mm

Treatment

Ultrasonic cleaning and curettage of the pocket
under local anesthesia

Oral hygiene instruction

Following the TOOTH guidelines



initial situation

Following the TOOTH guidelines for an angular bone defect

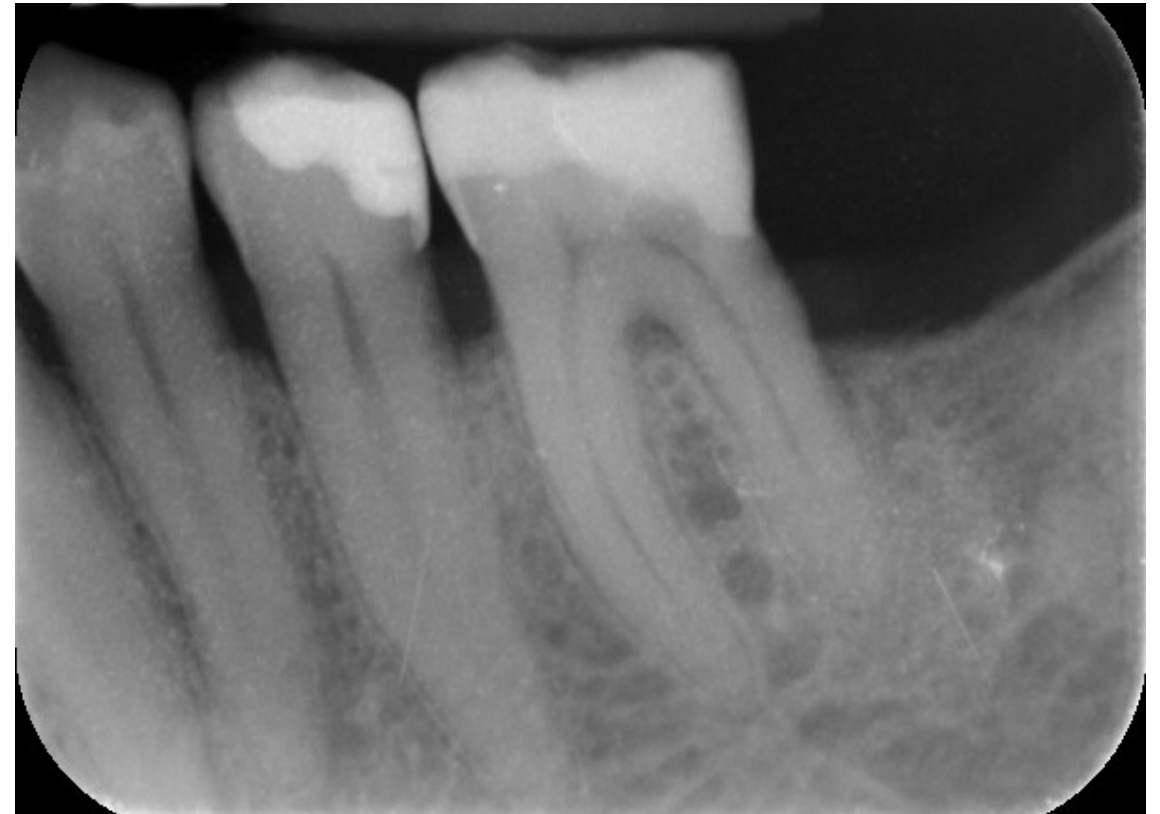
case report

After 2 years of strictly following the TOOTH guidelines

Growth of new bone distal of the 36

Pocket reduced to 4 mm

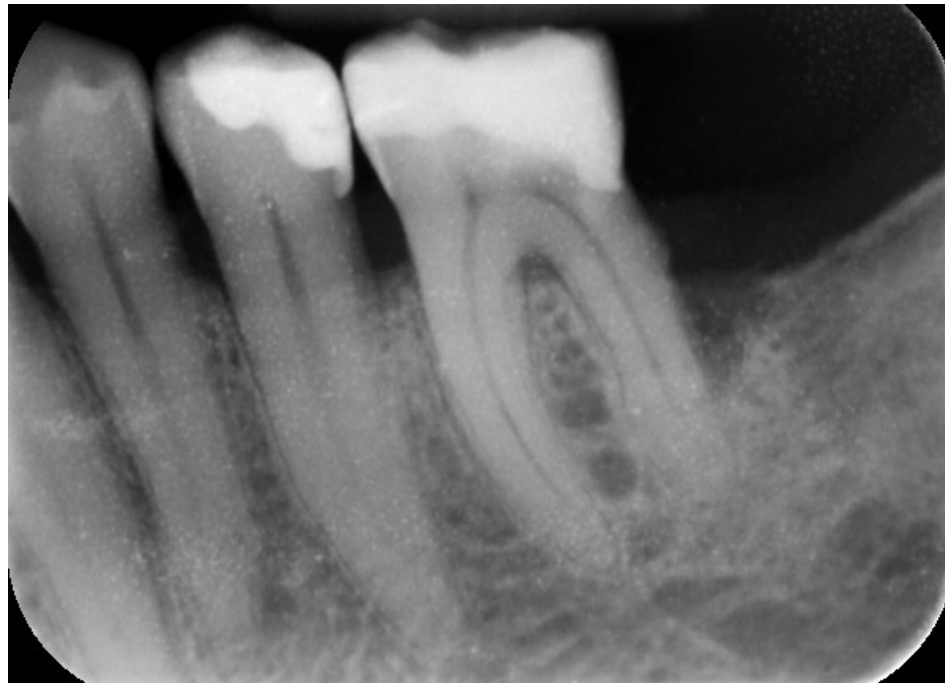
Bone level is equal on the mesial and distal side



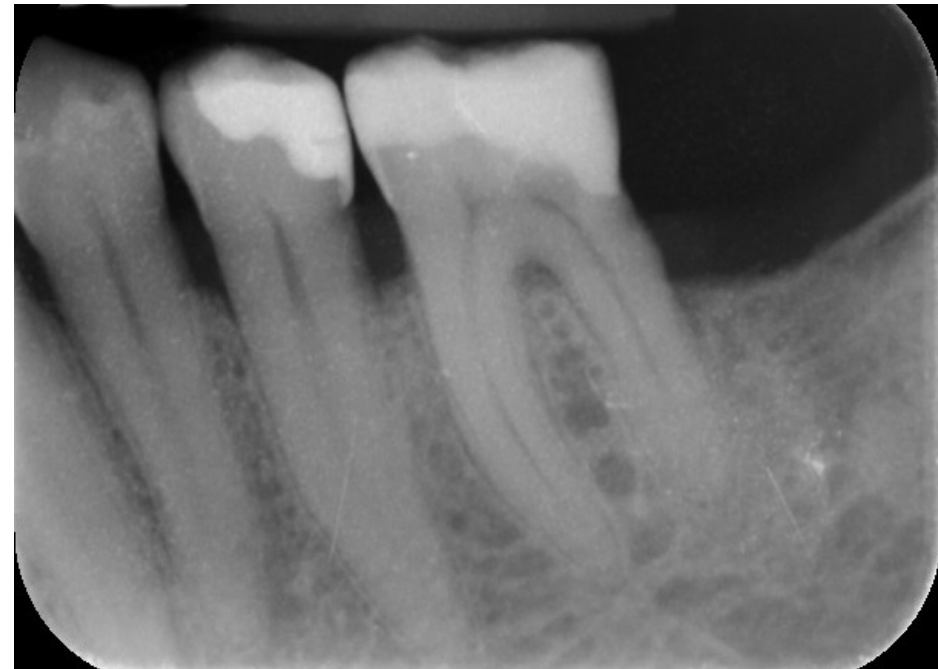
after 2 years of TOOTH

Following the TOOTH guidelines for an angular bone defect

case report



initial situation



after 2 years of TOOTH