



Following the TOOTH guidelines for peri-implantitis: a 2-year follow-up

Drs. R.A Muts

### Anamnesis

Male, 39 years old

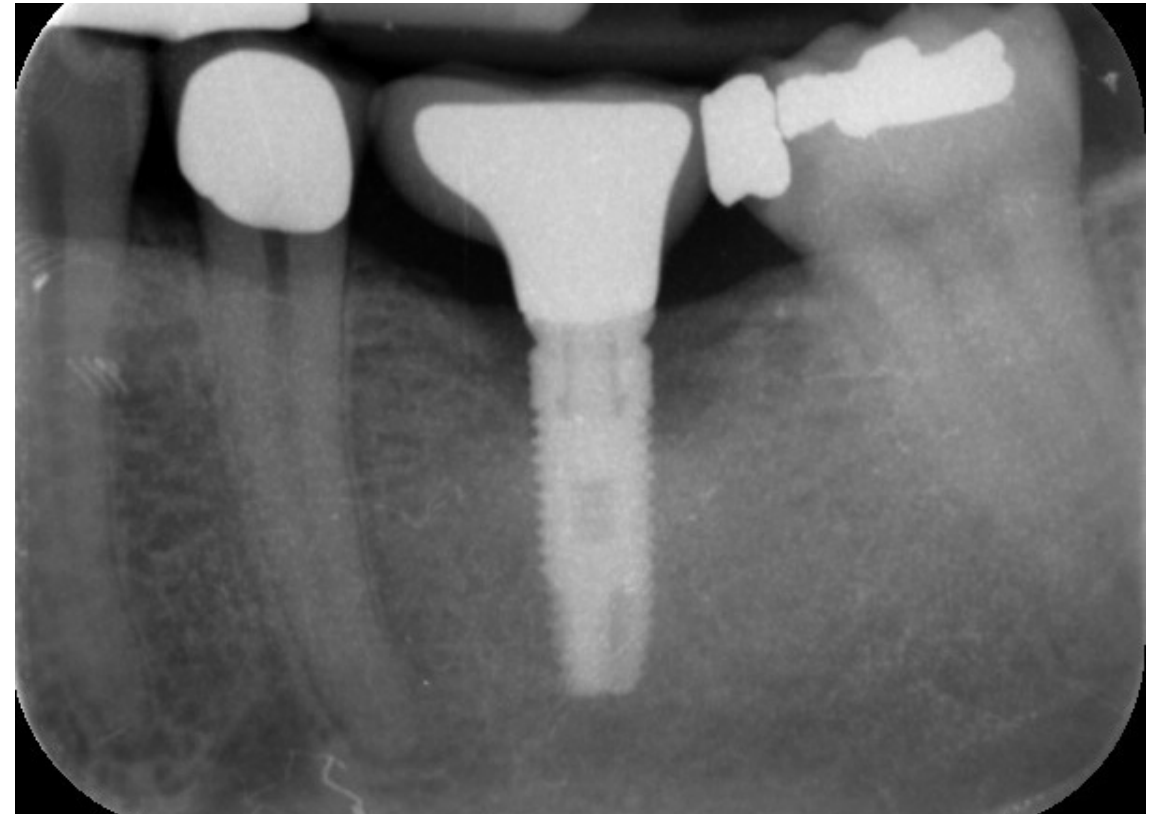
Peri-implantitis around 36 with a circular bone defect and a 9 mm pocket

### Treatment

Comprehensive oral hygiene instruction

Curettage around the implant under local anesthesia; not cleaning the implant surface

Following the TOOTH guidelines



initial situation

# Following the TOOTH guidelines for peri-implantitis

## case report

### After 1 year

Growth of new bone, both in horizontal and vertical direction

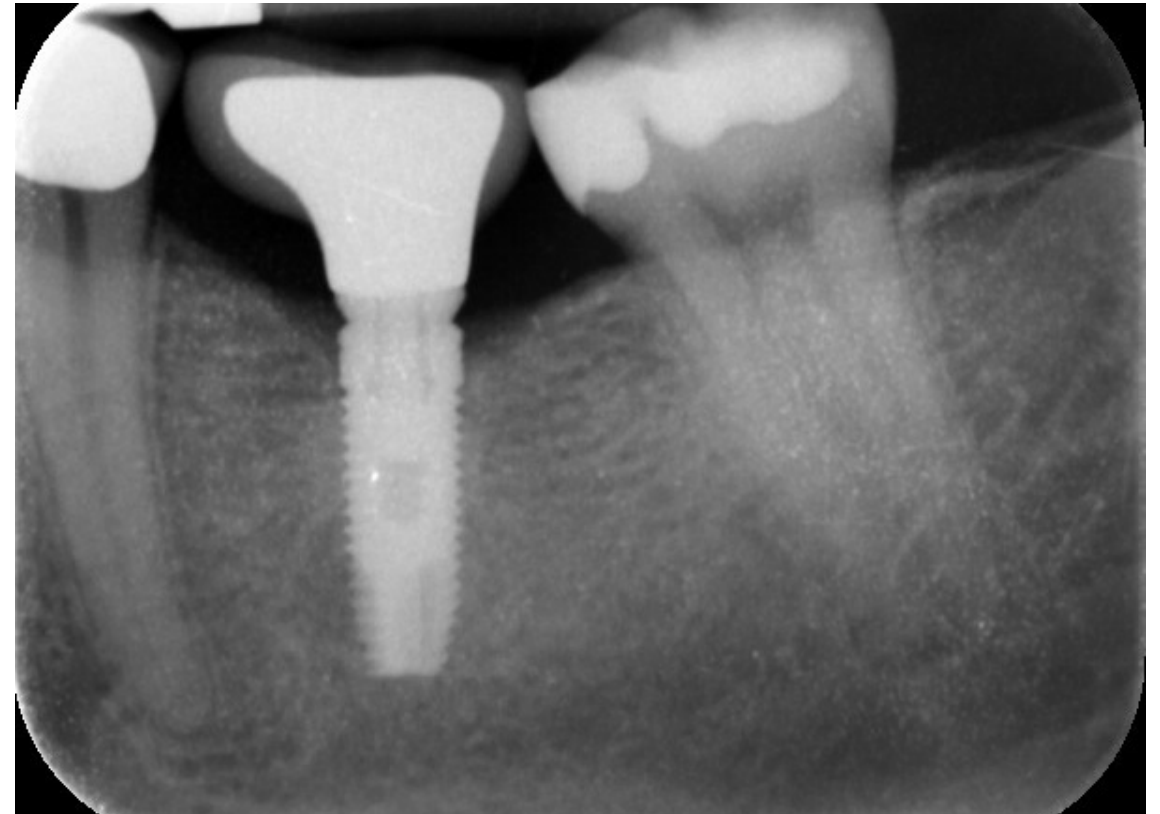
Pocket reduced to 4 mm

No redness and swelling

No bleeding on probing

Mucosa fits tightly around implant

Patient still follows the TOOTH guidelines



after 1 year of TOOTH

# Following the TOOTH guidelines for peri-implantitis

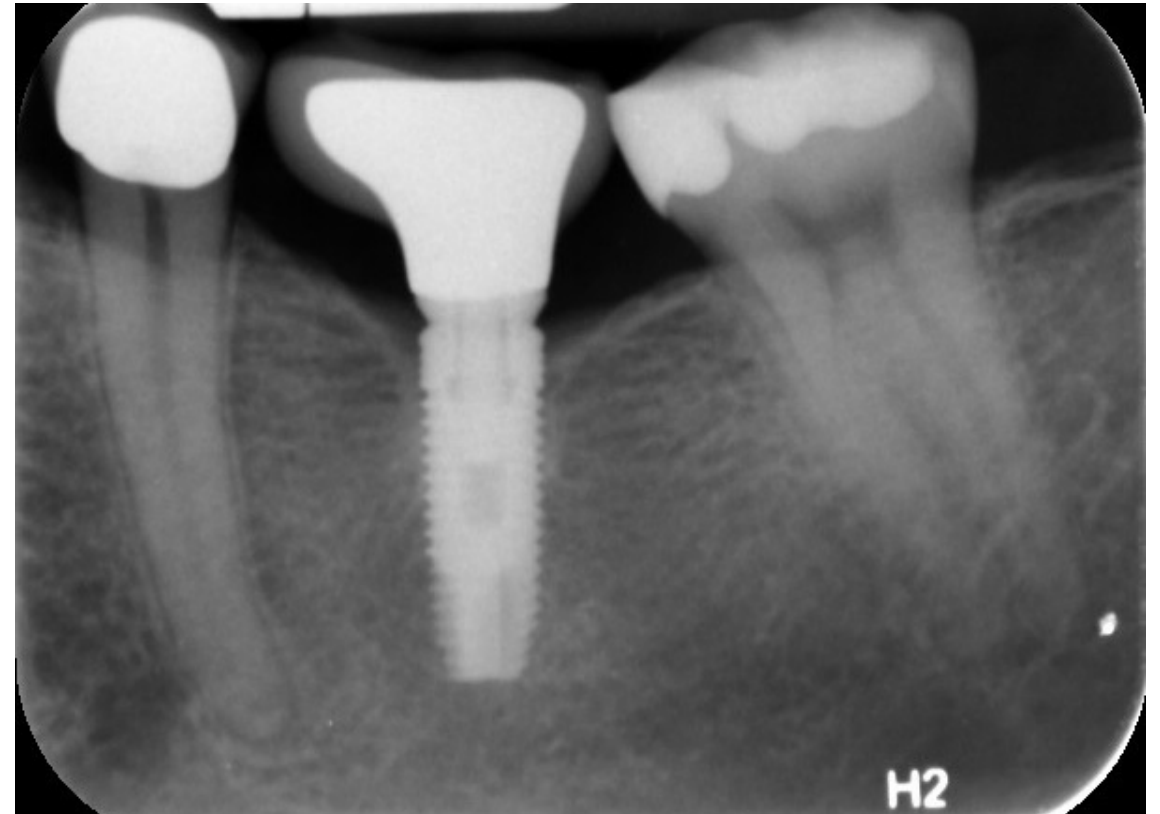
## case report

### After 2 years

No more loss of bone

Small pocket reduction to 3 mm

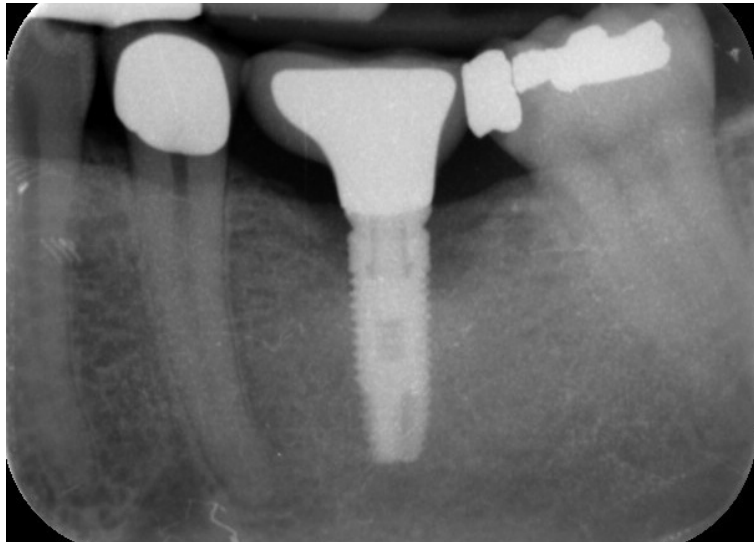
Patient still follows the TOOTH guidelines



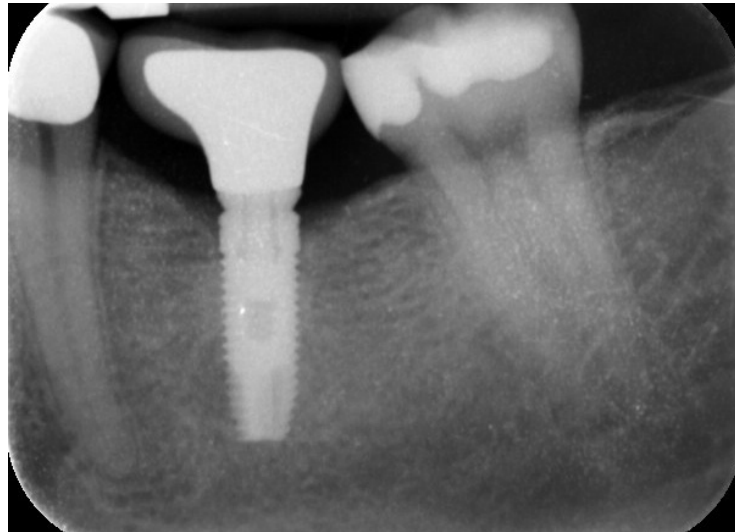
after 2 years of TOOTH

Following the TOOTH guidelines for peri-implantitis

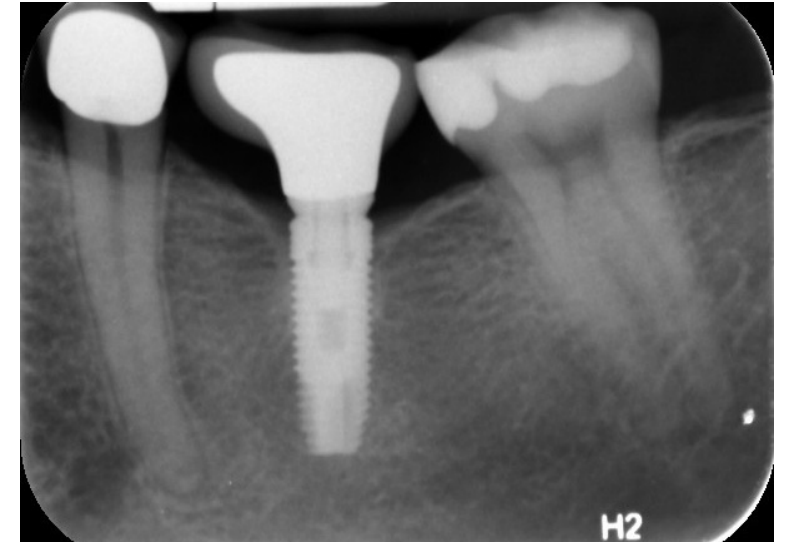
case report



initial situation



after 1 year of TOOTH



after 2 years of TOOTH